

CBH [redacted]

ONTARIO HOSPITAL, School, ORILLIA.

Electroencephalography Department

Case No. [redacted]

EEG. No. 3819

Name [redacted]

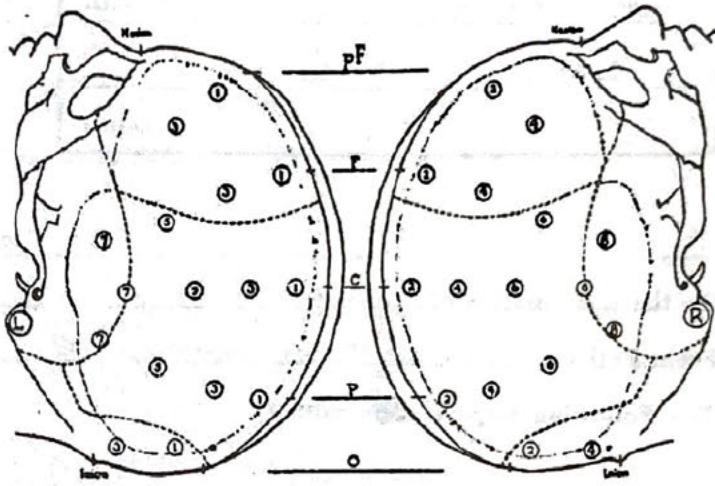
Age 6 yrs. Time

Date Apr. 30/65

MEDICATION:

REPORT: (Dr. [redacted])

ELECTRODE PLACEMENT:



Child was sedated (Nembutal grs. iii - Paraldehyde Z iii) asleep during examination..

In the anterior areas, moderate to moderately high voltage sharp spindle activity associated with occasional slow wave activity - this did not appear to be a typical seizure type activity.

In the post central areas, irregular slow activity with some fast activity superimposed.

In deep sleep, considerable slow wave activity appeared in all areas.

Photic stimulation induced no change.

No focal or definite seizure activity seen.

File
a

[redacted signature block]

b.