

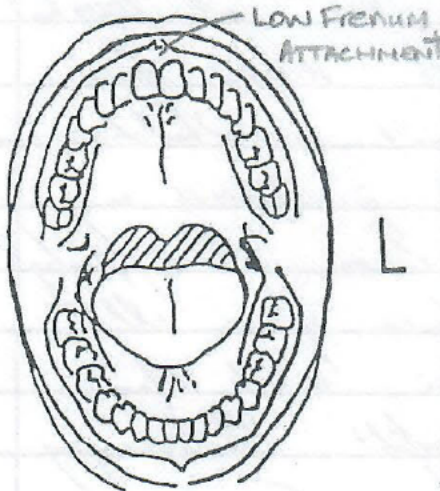


Name [REDACTED] Location MRC Casebook Number [REDACTED]

Date	<u>11/20/92</u>								
Lymphatics									
TMJ									
Lips	<u>WNL</u>								
Buccal Mucosa	<u>HYPERPLASIA</u>								
Floor of Mouth									
Tongue									
Hard Palate									
Soft Palate									
Pharynx									
Initials	<u>[REDACTED]</u>								

Initial Soft Tissue Exam Date Nov 20/92

Initial Periodontal Exam



Initial TMJ

Pain: L  R \_\_\_\_\_  
 Crepitus   \_\_\_\_\_  
 Popping   \_\_\_\_\_

Initial Occlusion

Class I II III  
 Overjet \_\_\_\_\_ MM. Slide \_\_\_\_\_ MM.  
 Midline \_\_\_\_\_ Crossbite \_\_\_\_\_ Overbite \_\_\_\_\_  
 Profile \_\_\_\_\_  
 Molar Relation: Left \_\_\_\_\_ Right \_\_\_\_\_  
 Cuspid Relation; Left \_\_\_\_\_ Right \_\_\_\_\_  
 Habits:  Thumb  Tongue

Inflammation:  Severe  Moderate  Light  
 Plaque:  Generalized Area \_\_\_\_\_  
 Bleeds on Probing  
 Calculus:  Heavy  Moderate  Light  
 Supra  Sub  Stain  
 Oral Hygiene:  Poor  Fair  Good  
 Smoking:  Yes  No  
 Attached Gingiva:  Pink  Red  Magenta  
 Stippled  Glossy  Granular  
 Consistency:  Firm  Boggy  Fibrous  
 Margins:  Thin  Swollen  Receded  Irregular  
 Papilla:  Pointed  Blunted  Flat  Inverted  
 Pink  Red  Magenta  
 Firm  Boggy  Fibrous  
 Pocketing:  Generalized Area \_\_\_\_\_  
 Diagnosis:  Mild Periodontitis  Moderate Periodontitis  
 Advanced Periodontitis  Gingivitis  
 Other \_\_\_\_\_  
 Etiology:  Dilantin  Other \_\_\_\_\_

Initial Radiography Exam

Bone Loss \_\_\_\_\_ Bony Lesions \_\_\_\_\_  
 Furcations \_\_\_\_\_ Impactions \_\_\_\_\_  
 Unfavorable C/R Ratio \_\_\_\_\_  
 Tooth Development \_\_\_\_\_  
 Other \_\_\_\_\_  
 Remarks \_\_\_\_\_