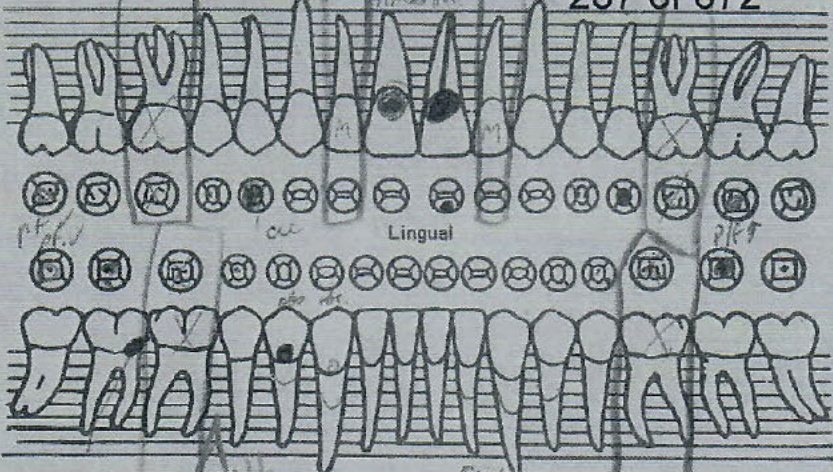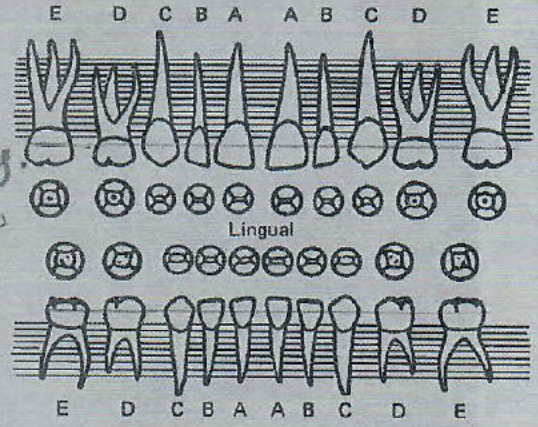


ORAL INDICES
 ORAL HYGIENE: poor
 DEBRIS, STAIN, CALCULUS
 PERIO. CONDITION: poor severe
 GINGIVITIS, BONE LOSS, bleeding
 TOOTH MOBILITY,
 RECESSION, HYPERPLASTIC
 POCKETS, VINCE NT'S

	DENTURES		
	Pre-scribed	Used	
Yes	No	Yes	No
Full Upper			
Full Lower			
Partial Upper			
Partial Lower			

OCCCLUSION:
 CLASS I CLASS II CLASS III
 OVERBITE 2 mm OVERJET 2 mm



DIAGNOSED CONDITION PROFOUND
 DRUGS USED REGULARLY antibiotics, epilepsy, anticonvulsants
 LIVER, LUNG OR KIDNEY DISEASE none
 HEART DISEASE, HIGH BLOOD PRESSURE none
 DIABETES, RHEUMATIC FEVER, BLOOD DYSCRASIAS none
 ALLERGIES none
 REACTION TO LOCAL ANAESTHETICS none known
 REACTION TO ANTIBIOTICS OR DRUGS none known
 BEHAVIOUR PROBLEMS YES NO SEDATE 2/1/88/15'
 SEDATION REQUIRED PRIOR TO DENTAL TREATMENT yes
 GENERAL ANAESTHESIA REQUIRED no

DATE	INITIAL	SERVICE	DATE	INITIAL	SERVICE
Dec 13/79	[REDACTED]	Oral Exam + Prophylaxis	Sept 14/80	[REDACTED]	under local. 470 - dental x-ray +
Dec 14/79	[REDACTED]	U - consent + initiate + bed			amalgam - fluoride to 445 430
Oct 24/80	[REDACTED]	oral exam + prophylaxis + fluoride			polished 11 21 + fluoride
July 8/80	[REDACTED]	oral exam + prophylaxis + fluoride	April 21/80	[REDACTED]	Oral Exam + Prophylaxis
	[REDACTED]	poor OH, abundant plaque - mucal root	Sept 29/80	[REDACTED]	recall exam, brush in on ward OAT
	[REDACTED]	decay (shallow demineralization)	Sept 24/80	[REDACTED]	recall exam, scale + prophyl
Sept 4/80	[REDACTED]	under local - 11 B, 12, 21, 22	Oct 27/80	[REDACTED]	nitrofurazone sealant + rubber dam
	[REDACTED]	dy + varn + amalgam - deep decay			isolation #27.
	[REDACTED]	21 - possible pulpal involvement + indirect	May 25/81	[REDACTED]	Oral Exam + Prophylaxis
	[REDACTED]	ulcer - 370 - dy + varn + amalgam	July 21/81	[REDACTED]	2 Litmex 1 (0.2cc) 1/2cc 10' eqn
Sept 9/81	[REDACTED]	oral exam - prophylaxis - 11, 21			450 + 150 - Delton pit - fissure
	[REDACTED]	30mg (40 tab) - for peris (propia)			sealant placed
	[REDACTED]	edema + redness at sulcus	Oct 4/84	[REDACTED]	Brush - in on ward - poor peris
	[REDACTED]	near abundant plaque			

EACH TREATMENT RENDERED MUST BE RECORDED, DATED AND IN ALL X-RAYS ETC. MUST BE RECORDED.

NAME

DATE	INITIAL	SERVICE	294 of 672	DATE	INITIAL	SERVICE
Nov 4/86	JP	2-1- RCT - NECROTIC DEBRIS		Nov 11/86	JP	SEB # FOR THURS NOV 13/86
		VITAL TISSUE - # 70 FILE				NEHA (ORAL) 200 MG +
		IRM - I.P.A. - NUSK, PELL FC				DEMEROL (ORAL) 50 MG -
		CAUIT - GOOD GUY - INC LENGTH				ADMIN. AT 07:15 HR FOR
Nov 10/86	JP	SECTION FOR THURS NOV 13/86		Nov 10/86	JP	08:30 HR. - NO BREAKFAST -
		NEHA (ORAL) 200 MG +				2-1- LINC COMP RESIN, REPLACE
		DEMEROL (ORAL) 50 MG -				VAMAL E COMP RESIN - 2X1X
		ADMIN AT 07:15 HR FOR 08:30				CC. PRILOR 0 1:200,000 EPINEPH.
		HR ADPT - NO BREAKFAST.				I.P.A. - SOMEWHAT RESTLESS
Nov 13/86	JP	2-1- RCT - CLEAN + SHAPE				Today
		CANAL #50 - 21 MM TO APTX.		11/15/86	JB	Exam. No cancer evident.
		GC BURDS UTILIZED - FILL E.G.P.				Generalized calculus - 4th Plan -
		+ PRECISE - C+B CEN. BASE.				Max. infl + mand. Wkds. Cavities
		CAUIT - REQ - V+ LING RESIN.				Richard / app. Good balance
	SIGNATURE	INITIAL		SIGNATURE	INITIAL	
	SIGNATURE	INITIAL		SIGNATURE	INITIAL	
EACH TREATMENT RENDERED MUST BE RECORDED, DATED AND INITIALED. ALL X-RAYS ETC. MUST BE RECORDED.						
NAME						

293 of 672

NAME	DATE	INITIAL	SERVICE	NAME	DATE	INITIAL	SERVICE
	Jan 24 89	MA	Rx: Sedation for Thurs. Feb. 2 89. Nembutal 200mg po + phenergan 50 mg po. Admin med's 07:30 for 08:30 app. NO BREAKFAST please.		FEB 28 90	YU	SEND IN ORDER FOR WED. FEB 28 90 AT 0830HRS NEMBUTAL 200mg (P.O.) + DEMEROL 50mg (P.O.). ADMIN MED'S 0730HRS. NO BREAKFAST & TRANSF W/CHAIR.
	FEB 28 89	Wh	Recall Ham, tooth, probing Poor OH. min. electric pulp Electrovis. gingivectomy of Pd out. 33-43 Sedation very effective. Rx: Tyl #2 Tylstat Chl i gel x 2 days qh		FEB 28 90	YU	RECALL EXAM, SCALING - OH POOR BREATH IS TERRIBLY FOUL. 33-43 - MAL - PARASITIC VERY INFLAMED + RED. DEEP SCALING IN THIS AREA ALSO WILL REASSESS - DMW AFTER ANTIBIOTIC THERAPY + FOH (usual) CULTURE (10.04%). TEETH 33-43 MAY REQUIRE MORE SURG / EX'N. 1-17 OF MD INCISORS. Rx: SPIRAMYLIN 500mg 2x/day x 10 days CALHEX (O.W) 5ml 1x/day x 10 days AVOID

NAME

DATE

INITIAL

SERVICE

291 of 672^E

INITIAL

SERVICE

Sept 4/90 Sedation Order Sept 2/90
Admin Nembutal 200mg
p.o. + Demerol 50mg p.o.
@ 0800 Hrs for 0900 Hrs
appt. No breakfast
please. Transport in
MB wheelchair

OH: Very bad - dilant in hypop.
extensive

Behavior: Very bad but
if no prep handled better.
So needs more sedation
& try to prep next time
no cancer detected
but need to assess
again once OH better.

Leave ^{02:00} CHX to counsellor
to be used on ward
2 daily on toothbrush
NPO 15 Ls after each brush.

Will need chemo
Md admission - assess

next appt.

Sept 12/90 Cancel Sedation Order
for Sept 12/90
New Sedation order
for Sept 26 @ 10³⁰
Admin same Rx @
MB 9³⁰. NO BK. Trans. in WC

Sept 26/90 Recall appt: exam, scaling
propyl, CHX brush

MB

DATE

[REDACTED] 292 of 672 [REDACTED]

SERVICE

<p>MARCH 15, 89 YW</p>	<p>SWALLOWING. OUT WITH STAFF - COTTALE ID. CHECK ON TISSUES - LABIAL 33-43, LOOK MUCH BETTER, BUT STILL RED + SWOLLEN + DIFFICULT TO ASSESS ATTACHMENT LEVEL, WILL REASSESS IN A FEW DAYS ALTHO OH - STILL POOR - ALOT OF FOOD + PLAQUE ON POSTERIOR - BRUSHED W 0.04% CHLHYD'N SOL'N. BEHAV - DIFFICULT TOWARDS THE END OF APPT.</p>	<p>MARCH 15, 89 YW CHECK IN LABIAL TISSUE - NO PROBLEMS, ONOCCIDENTAL IMPROVE LOOK MUCH BETTER BUT WILL REQUIRE ESURE TO REMOVE EXCESS TISSUE - LABIAL 31-41, BRUSHED W 0.04% CHLHYD. VISITED COTTALE IF DISABLED IMPROVE OF MAINTAINING THIS IMPROVED STATE OF OH, WILL KEEP THESE TEETH AS LONG AS POSSIBLE DESPITE WRY MAG. @ SURG AT NEXT REGAL APPT UNDER SED'N. - 6 mos. VISIT TO COTTALE TO IMPROVE OH IMPROVED OH</p>
------------------------	--	--

<p>SIGNATURE [REDACTED] INITIAL [REDACTED]</p>	<p>SIGNATURE [REDACTED] INITIAL [REDACTED]</p>
--	--

✓ EACH TREATMENT RENDERED MUST BE RECORDED, DATED AND INITIALED BY THE DENTIST
 ALL X-RAYS ETC. MUST BE RECORDED.

NAME [REDACTED]

DATE	INITIAL	SERVICE	INITIAL	SERVICE
		290 of 672		
May 9/91		Reduction ordered for them		hyperplasia of mouth prop
		May 10/91 @ 10:45		Behavior: poor. resistant to
		Mental 200 mg	MT	oral mouth prop before &
		Demerol 25 mg		sed procedure
		Phenergan 25 mg	May 14/91	Recall exam, scale properly
		Admin meds orally in		on pain profuse gingival
		SCU at 08:30 No		bleeding & some of getting
		breakfast. Transport in		& mobility Behavior: good
		MT wheelchair		responsive, talkative, gagger
May 16/91		Recall exam, scale, properly		to mouth prop diff opening
		on poor abundant plaque	MT	with
		albin calculus profuse		
		gingival bleeding & some		
		& pathology PO gingival		
	SIGNATURE	INITIAL	SIGNATURE	INITIAL
	SIGNATURE	INITIAL	SIGNATURE	INITIAL
EACH TREATMENT RENDERED MUST BE RECORDED, DATED AND INITIALED BY THE DENTIST ALL X-RAYS ETC. MUST BE RECORDED.				
NAME				

